



Owner's Copy

PennHIP Report

Referring Veterinarian: Dr Steven Metcalfe Email: steve@applecrossvet.com.au	Clinic Name: Applecross Veterinary Hospital Clinic Address: PO Box 891 Canning Bridge, ACT 6153 Phone: 6 (189) 364-7666 Fax:
---	--

Patient Information

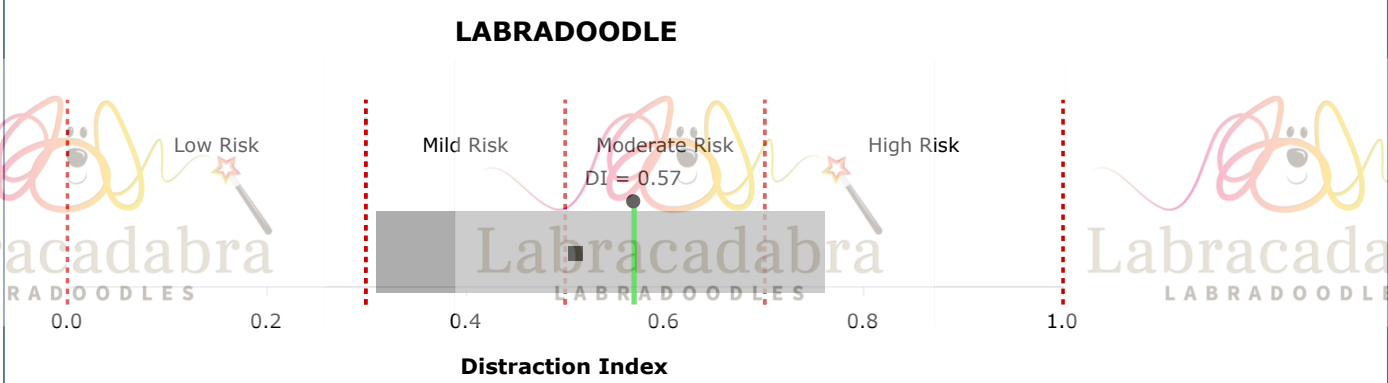
Client: Leiper, Jessica Patient Name: Blink Reg. Name: Bellissimo Cherry Ripe PennHIP Num: 137077 Species: Canine Date of Birth: 06 Jul 2019 Sex: Female Date of Study: 25 Nov 2019 Date of Report: 27 Nov 2019	Tattoo Num: Patient ID: 101350 Registration Num: 0147-062-11 Microchip Num: 953010004038261 Breed: LABRADOODLE Age: 20 weeks Weight: 25.6 lbs/11.6 kgs Date Submitted: 25 Nov 2019
---	---

Findings

Distraction Index (DI): Right DI = 0.57, Left DI = 0.55.
 Osteoarthritis (OA): No radiographic evidence of OA for either hip.
 Cavitation/Other Findings: No cavitation present.

Interpretation

Distraction Index (DI): The laxity ranking is based on the hip with the greater laxity (larger DI). In this case the DI used is 0.57.
 OA Risk Category: The DI is between 0.50 and 0.69. This patient is at moderate risk for hip OA.
 Distraction Index Chart:



BREED STATISTICS: This interpretation is based on a cross-section of 7486 canine patients of the LABRADOODLE breed in the AIS PennHIP database. The gray strip represents the central 90% range of DIs (0.31 - 0.76) for the breed. The breed average DI is 0.51 (solid square). The patient DI is the solid circle (0.57).

SUMMARY: The degree of laxity (DI = 0.57) falls within the central 90% range of DIs for the breed. This amount of hip laxity places the hip at a moderate risk to develop hip OA. No radiographic evidence of OA for either hip.